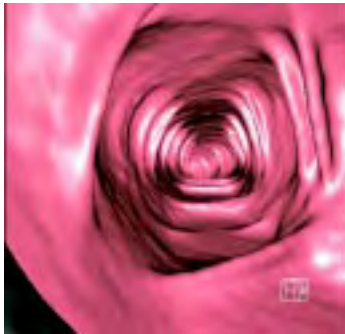



CT Virtual Colonoscopy has been in the news and a recent report from *the New England Journal of Medicine* (349:23, 2191-2200) endorses its use. "CT virtual colonoscopy with the use of a three-dimensional approach is an accurate screening method for the detection of colorectal neoplasia in asymptomatic average risk adults and compares favorably with optical colonoscopy in terms of detection of clinically relevant lesions."

Pueblo Radiology employs the newest 3D software available



for the performance of CT Virtual Colonoscopy and has two years experience with the technique. At this time, all of our colon studies are double read. The following are important facts related to CT Virtual Colonoscopy.

What is CT Virtual Colonoscopy?

CT Virtual Colonoscopy, also called Virtual Colonography or CT Colonography (CTC) is the newest, most advanced non-invasive method for colon cancer screening. This new method allows doctors to examine the large bowel (colon) to detect polyps and other forms of cancer. Polyps are small growths in the colon that may become cancerous if they are not removed.

Who should have a CT Virtual Colonoscopy?

CT Virtual Colonoscopy is an appropriate screening option for the following individuals:

- **50+ years of age**
- **Family history of colon cancer**
- **Unsuccessful colonoscopy in the past**
- **Persons unable to undergo anesthesia**
- **Any person needing a screening examination of their colon.**

Has this been scientifically studied?

Research performed at university centers has shown

that Virtual Colonoscopy is better able to see polyps than a double contrast barium enemas. It is also nearly as accurate as conventional colonoscopy for polyps most likely to become cancerous.

Virtual Colonoscopy Facts

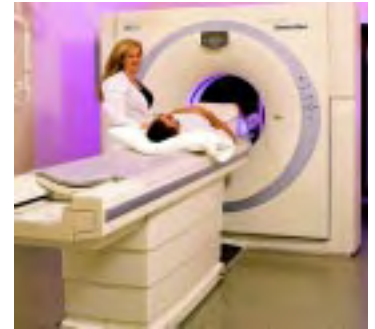Why is it important?

Colorectal cancer is a leading cause of cancer related deaths in the United States. Approximately 140,000 cases of colon cancer will be diagnosed in the U.S. this year and 60,000 patients will die of the disease. Colon cancer can be prevented if polyps are discovered and removed early. Individuals at greatest risk of developing colorectal cancer remain largely under screened due in part to lack of public awareness and poor acceptance of current screening colonoscopy techniques. At present only 15% of all colons that need to be screened are being screened using standard colonoscopy.

How is a CT Virtual Colonoscopy done?

The basis of the test is a CT scan of the colon using ultrathin (1mm) slices while the colon is inflated with gas. This allows

radiologists to interpret pictures on a computer with software that creates images similar to those seen by conventional colonoscopy. Patients need a cleansing preparation of their bowel prior to the test. The actual CT Virtual Colonoscopy procedure will begin by inserting a small flexible tip into the rectum so that CO2 can be



gently introduced. A CT scan is then performed with the patient supine and then prone. The total time required for the study is 20-30 minutes. Because sedation is not required, patients are free to leave the CT center immediately without the need of observation. Patients can resume their normal activities immediately after the procedure. The Radiologist will analyze the CT data and the physician will receive a copy of the patients report within 24 hours.

Pueblo Radiology Provides Quality Outpatient Service for Dialysis Patients

In response to a community need for prompt dialysis access treatment, Pueblo Radiology has been providing this service in our Ventura Imaging Center. Hemodialysis patients require three dialysis sessions per week and any delays in treatment because of access malfunctions can cause serious health problems. Local hospital cath labs are frequently too busy to treat these patients promptly and dialysis centers

schedules are then disrupted by these availability problems.

We have three Board Certified Interventionalists who have many years of experience with hemodialysis access interventions. They are particularly skilled in the re-opening of clotted dialysis cath by thrombolysis and angioplasty. We also insert temporary dialysis catheters, both tunneled and non-tunneled, when needed.

Pueblo Radiology has been working closely with local dialysis centers and surgeons to promptly treat access problems in these patients, frequently returning them for dialysis the same day. The dialysis centers have been very pleased with our prompt service and we have become the preferred site for consultation and treatment.

The outpatient setting has become more important in the delivery of

interventional services, which include biopsies, varicose vein treatment, spinal injection procedures, and other minor invasive procedures.

Our interventional staff is happy to consult with you or your patients regarding an imaging guided invasive procedure. Pueblo Radiology is committed to providing prompt quality service in a friendly professional outpatient setting.

Non Invasive Angiography—When to use CTA vs. MRA

Introduction

The development of fast multirow detector CT scanners and MRI scanners with faster and more powerful gradient coils has allowed us to replace many diagnostic catheter angiograms with less invasive imaging techniques. These techniques have become well established in assessment of the carotid arteries, pulmonary and renal vasculature, and for aneurysms of many types. More recently, these techniques are replacing catheter angiography in assessment of peripheral vascular disease in the lower extremities. Many of these clinical problems can be imaged with either CT angiography (CTA) or magnetic resonance angiography (MRA). This article is intended to help clinicians learn how these techniques work and when to order a CTA vs. MRA.

Technique

Contrast enhanced CTA and MRA (CEMRA) make images of blood vessels using a "first pass" technique. In CEMRA, it is common to perform precontrast imaging and subtract these from the postcontrast images to improve contrast resolution, resulting in an image in which only vascular structures are bright. With both CTA and CEMRA computer postprocessing is important in rendering axial or coronal source images into a picture resembling a catheter angiogram. This is most commonly done with a maximum intensity pixel (MIP) ray tracing technique. These images, resembling traditional angiograms, are available within a few minutes. More advanced thin-slab MIP, multiplanar reconstructions (MPRs), and volume rendering

techniques on a powerful computer workstation are used by the radiologist when needed for interpretation. With CTA, typically 100cc of iodinated contrast is injected. With CEMRA, 40cc of gadolinium-based contrast agent is injected via a power injector. Noncontrast MRA is also possible using time-of-flight (TOF) technique.

TOFMRA

Advantages:

- No contrast injection.
- High proportion of scans result in acceptable images
- Performed at the same time as routine brain imaging on the MRI scanner.
- Rapid, standardized post processing

Disadvantages:

- Scan more susceptible to motion due to longer scan time.
- Helpful when normal but can overestimate stenoses due to turbulent flow which introduces artifacts.
- Can't be used for large volumes, long vessels.
- Works best when vessels are flowing perpendicular to the imaging plane, so in-plane vessels can be less well seen.
- MRI exams are contraindicated on patients with pacemakers
- Hemostatic or Aneurysm clips can obscure the area of interest.
- Claustrophobic patients can be a problem.

Common uses: Carotid bifurcations, Circle of Willis.

First choice for: screening for brain aneurysms in an asymptomatic but higher risk patient.

CEMRA

Advantages:

- Very high contrast resolution.
- More robust technically than CTA.

- Faster and easier to post process since bony structures and other overlapping anatomy is already dark or masked out with subtraction techniques.
- Can be used in azotemic patients and repeated after a short interval for contrast excretion.
- A wide field of view can be covered in one acquisition.
- Less affected by vessel calcification.

Disadvantages:

- Slightly lower spatial resolution compared with CTA
- Slightly more expensive
- Claustrophobic patients, pacemakers, and metallic clips are problematic.

Common uses: Carotids, Circle of Willis, renal arteries, abdominal aorta, lower extremities.

First choice for: Arch, cervical carotids and cerebral circulation; heavily calcified vessels where CTA is difficult to interpret. Robust, reproducible, standardized lower extremity runoff arteriograms. Renal arteries in patients with azotemia.

CTA

Advantages:

- Highest spatial resolution (sub millimeter).
- Wide coverage possible in one acquisition with our fast Siemens scanner.
- Best choice for coronary arteries, pulmonary arteries because of its motion-stopping speed.
- Nonvascular pathology is often identified.
- Not affected by turbulent flow in vessels.
- A normal CTA excludes renovascular hypertension with near 100% reliability. (Ref.1)
- Better at stopping pulsation in the aortic arch than CEMRA.

Disadvantages:

- Requires iodinated contrast injection via larger IV catheter (18ga.)

- Overlap of bony, calcified, or metal structures can be problematic and complicates post processing, especially at skull base.
- Takes more radiologist and technologist time to post process at present.
- Less tolerant of timing variation in contrast bolus (patients with poor cardiac output) and venous contamination of arteriograms is more common than CEMRA.

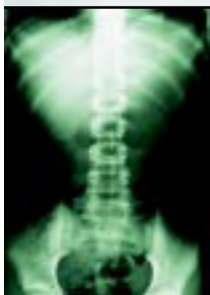Common uses: Pulmonary arteriography for suspected PE, aortic aneurysms and dissections, stent graft planning and postop assessment, carotid stenosis problem solving, renovascular disease, splanchnic vasculature. Runoff assessment in patient with severe arterial insufficiency and contraindication to MRI, or if higher resolution is needed than MRI for a specific vascular lesion.

First Choice For: Renovascular evaluation (arteries or veins) in a patient with normal creatinine clearance. Best test when results of carotid ultrasound and MRA don't agree. Noninvasive workup for possible coronary artery disease. Aortic aneurysms, dissections, suspected PE, stent grafts, suspected splanchnic ischemia.

If you have any questions about which non-invasive vascular imaging study is best for your patient please call 682.6219 to speak to a radiologist. You can also email John D. Wrench, M.D. at jwrench@puebloradiology.com with questions any time.

References:

1. Prokop M: CT angiography of the abdominal arteries. *Abdom Imaging* 23:462-468, 1998.



Pueblo Radiology Now Offers X-Ray Exams in Oxnard

To conveniently serve your patient's needs, Pueblo Radiology is performing conventional diagnostic x-rays at our new Oxnard site. The office is located inside the Oxnard Industrial Medicine Clinic.

345 South A Street. Oxnard, CA 93030

Phone: (805) 240-7746 Fax: (805) 654-8173

Open Monday through Friday 8:30 am. to 5 p.m.

Closed 12-12:30 p.m. for lunch

Meet the Pueblo Team

Daniel Fox M.D. Radiologist



Dr. Fox was born and raised in Southern California. Early in life he took on financial responsibilities by helping to support himself and family by working after school as a cashier, file clerk,

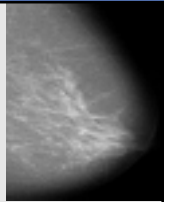
service station manager and neighborhood gardener. He balanced school work and employment responsibilities with after school sports and ocean recreation. He was able to finance his undergraduate education at UCSD's Revelle College by continuing full-time work in local biotech firms. Initial work as a technician in an immunology laboratory evolved into a molecular biology research assistant position at the Salk Institute.

Professional success began early with his discovery and characterization of novel human genes and publication in respected scientific journals such as Science. Despite his passion for basic

sciences, he decided to continue his education in the field of medicine and attended Eastern Virginia Medical School, graduating AOA and first in his class. His medical school success afforded him the opportunity to return to California where he trained at UCI as an intern, again graduating with honors. Subsequently, Dr. Fox trained in Diagnostic Radiology at UCLA where also served as Chief Resident. Fellowship training at USC/L.A. County Hospital prepared him for just about anything. Dr. Fox is proud to be a member of this medical community working with the respected Pueblo Radiologists.

Dr. Fox admits his success is in part attributed to the long standing support of his wife, Catherine, who has stood at his side since the early days of molecular biology. They are now excited to call Santa Barbara their home where they have lived for the past three years. Both are sure this is the finest area to raise their five-year old daughter, Sommer Rae. The natural beauties of the area and its people have enriched their lives.

2003 Breast Care Center Biopsy Results



In 2003, 192 needle core biopsies were performed on suspicious breast lesions at the Breast Care Center at Goleta Valley Cottage Hospital.

- 55 of the lesions or 30% had cancer.
- 71% of the cancers were less than 15 mm.
- 58% were less than 10 mm.
- 78% of the cancers were detected by screening mammography.
- Only 22% were detected by palpation.

Very small cancers are now diagnosed and patients usually do very well after their treatment. Patients whose biopsies were benign were spared surgery.

Our youngest cancer patient last year was 40 and the oldest was 93 years old. The percentage of women with cancer in their 40's was just as high as the percentage in their 50s. Our data validates the current recommendation that women at the age of 40 should start having an annual mammogram.

Brenda Pentecost

Santa Barbara-Front Office Coordinator



In our Santa Barbara office you have probably had an opportunity to speak with Brenda Pentecost. Brenda has worked for

Pueblo Radiology for 15 years. Brenda calls herself a "Jack of all Trades" having

started in the dark room, moved up to reception and now working as a coordinator in our patient registration services area. Her expertise in scheduling and billing issues makes her very valuable to Pueblo Radiology, its patients and to the referring physician offices of Santa Barbara. What Brenda loves most about her job is the patient contact. "I believe that our staff goes above and beyond for our patients. I feel so proud when we stay late to accommodate an ill patient" says Brenda.

When asked about the changes she has seen over the past 15 years, Brenda

points out the amount of technology now common at the Pueblo offices. "That we have become near paperless and filmless is absolutely amazing to me" says Brenda.

If you want to catch Brenda in the office, call before 2:30. After that she is dashing off to pick up her two children (ages 13 and 9) to get them to their afternoon activities. "Just call me a Sports/Dance Mom!" Like so many of you, Brenda's multitasking at work carries over to her personal life.

Linda Dodge

Ventura-Front Office Supervisor



Linda Dodge is the Front Office Supervisor for Pueblo Radiology-Ventura. Those of you who have come in contact with our office most likely

have had a warm welcome from Linda and shared a good laugh.

Linda has been working for Pueblo

Radiology since the opening of our Ventura location. Prior to this, she worked with our Medical Director Dr. John Stef and Dr. Dan Sommer at their former practice, Ventura Radiology, for 20 years.

Linda enjoys her responsibility of overseeing front office operations and staff. She makes sure that operations run smoothly, from scheduling patient appointments, admitting patients for their exam, to being last to see the patient leave having had a good experience. "What I love most is seeing how happy patients are when they leave the facility. It makes me very proud of our staff and the services we offer", says Linda.

Linda is a Ventura native, who has been married to her husband Frank for over 20 years. Together they have three boys ages 9, 10 and 15. They don't live like typical "Venturans" in that they grow their own food such as vegetables and fruits, and get their eggs from chickens they raise on their large plot of land.

Overall, Linda is a positive reflection on Pueblo Radiology. She is a hard worker, and a team player. "I enjoy being part of an imaging center that is on the cutting edge of technology" says Linda. Pueblo Radiology is happy to have Linda anchoring our front office customer service and registration operations.

Thank you for your support!

Pueblo Radiology just marked its one year anniversary that our Ventura site has been open. The physicians and staff of Pueblo Radiology would like to thank all of you who have supported us throughout the year.

When Pueblo Radiology opened in April of 2003, our mission was to answer the needs of the physicians and patients of Ventura County by providing you with local board certified radiologists, offering subspecialty expertise in neuro-radiology and interventional radiology. Efficient service, faxed reports and images on-line are some of the operational advantages that our practice brought to Ventura

physicians.

While offering you state-of-the-art technology, we introduced you to the digital world of radiology with the "Web Ambassador" PACS. This software allows your office to immediately access images & a "voice clip" impression, making your patients' images instantly available online for you to view in the comfort of your office.

Pueblo Radiology provides your patients with same day scheduling, STAT appointments and verbal reports available upon exam completion. You can depend on reports being transcribed and auto-faxed to your office within 4-12 hours. Films, paper images or CDs can be



delivered to your office upon request. Our Radiologists are always available on-site or for telephone or in-person consultations.

Pueblo Radiology strives to provide the best services and technology available that our competitors cannot match! Again, thank you for your support this past year and we look forward to continue doing business with you!

Inspiration for Cancer Survivors

Pueblo Radiology of Santa Barbara is very proud to have on display a jersey autographed by Lance Armstrong. Armstrong is a remarkable person who is the four-time Tour de France winner who fought a courageous battle defeating metastatic testicular cancer.

Dave Lettieri, a former Olympian and owner of the bike store "Fastrack" worked with Armstrong as his mechanic in the 2000 Tour de France. He was instrumental in getting Lance to sign this jersey for Pueblo Radiology last year, when Lance trained with the Postal Service Cycling Team in Santa Ynez. Armstrong signed this jersey in the hope that it will inspire patients who are battling cancer. A quote with the jersey says: "I am not a victim, I am a survivor."

The poster was created by graphic designer, Carlos Soto assembled by Christina Westerhouse of Frameworks and presented to Pueblo Radiology by the Santa Barbara cycling community. Please look for this display in the downstairs area of our Santa Barbara facility during your next visit.



Pueblo Radiology
ACR Accredited



Pueblo Radiology-Santa Barbara is accredited by the American College of Radiology (ACR) in CT, MRI and Ultrasound. Similar recognition is being submitted for our Ventura office. Mammography services are accredited at both sites.

These accreditations were received for achieving high practice standards based on a peer reviewed evaluation of our practice.

Pueblo Radiology- Santa Barbara

2320 Bath St., Suite 113
Santa Barbara, CA 93105
Phone (805) 682-7744
Fax (805) 682-3321

Pueblo Radiology- Ventura

4516 Market St., Bldg. 1A
Ventura, CA 93003
Phone (805) 654-8170
Fax (805) 654-8173

www.puebloradiology.com



Pueblo Radiology **Medical Group**
P.O. Box 1326
Santa Barbara, CA 93102

PRSR TD STD
US POSTAGE
PAID
SANTA BARBARA, CA
PERMIT #553